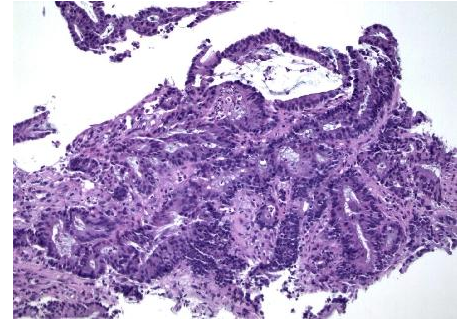


PATIENT INFORMATION	SPECIMEN INFORMATION		ORDERED BY
DOE, JOHN Sex: Male Age: 90, DOB: 03/05/1922 ACCESSION #: TR11-53114	COLLECTED:	10/04/2011	Alfredo Gomez, M.D. 5000 University Drive Miami, FL 33146 P: (305) 669-3471
	RECEIVED:	10/05/2011	
	REPORTED:	09/13/2012	
	CHART/MRN #:	65555	

FINAL DIAGNOSIS
COLON, ASCENDING, BIOPSY:

- **INFILTRATING ADENOCARCINOMA, MODERATELY-DIFFERENTIATED.**

COLON, ASCENDING, BIOPSY


**INFILTRATING
ADENOCARCINOMA,
MODERATELY-
DIFFERENTIATED.**

COMMENTS: The case is discussed with Dr. Gomez on 9/29/11

CLINICAL AND SPECIMEN INFORMATION

CLINICAL HISTORY: Screening colonoscopy.

ENDOSCOPIC FINDINGS: Napkin-ring lesion identified; firm on biopsy.

GROSS DESCRIPTION:

COLON, ASCENDING, BIOPSY: Three fragments measuring [Pieces] mm, [Size] mm, and [Pieces] mm.



Ana L. Viciano, M.D.

Electronically Signed: 9/13/2012

PATHOLOGY PERFORMED MARK AND KAMBOUR PATHOLOGY ASSOCIATES CLIA# 10D0952918

When required, some of the immunohistochemical tests performed by Mark & Kambour Pathology Associates had their performance characteristics determined by M&K. Although not cleared or approved by the U.S. FDA, the FDA has determined that such clearance or approval is not necessary. This laboratory is certified under the Clinical Laboratory Improvement Amendments of 1988 (CLIA-88) as qualified to perform high complexity clinical laboratory testing.

The information in this report is legally privileged and confidential. Its use is strictly limited only to those authorized. If you are not the intended recipient, you are notified that any disclosure of this information is legally prohibited. This report is the property of Mark & Kambour Path. Assoc.

If you received it in error, please call us immediately at 1-866-669-3471.